

---

## PEDIATRIC FUNCTIONAL ENDONASAL SINUS SURGERY: REVIEW OF 210 CASES

Rande H. Lazar, MD, Ramzi T. Younis, MD, and Charles W. Gross, MD

Functional endonasal sinus surgery (FESS) is an effective treatment for chronic or recurrent sinusitis in children, most of whom have failed more conservative medical treatment. The endoscopes used in FESS allow direct visualization of the diseased tissue and restoration of physiologic mucociliary clearance, enabling the sinus mucosa to return to its normal condition after the procedure. For a period of 3 to 36 months, we followed the recovery of 210 children who underwent FESS between 1986 and 1989. The age range of the children at the time of the procedure was 14 months to 16 years. Eighty percent of these patients had improvement of their sinusitis. There were no major complications. Eight percent of the 210 children needed revision surgery. Pediatric FESS is a two-stage operation requiring follow-up nasal cleaning under general anesthesia. The most common findings during the second-stage endoscopy were adhesions and granulation formation.

**HEAD & NECK 1992;14:92-98**

---

From the Department of Pediatric Otolaryngology (Drs. Lazar and Younis), Le Bonheur Children's Medical Center, Memphis, Tennessee; Department of Otolaryngology-Head and Neck Surgery (Dr. Lazar and Dr. Younis), Methodist Hospitals of Memphis, Memphis, Tennessee; and Department of Otolaryngology (Dr. Gross), University of Virginia, Charlottesville, Virginia.

Acknowledgments: For their professional contributions, we are indebted to Michael J. Guruchari, MD, Thomas E. Long, MD, Sherri L. Smith, RN, PNP, Kwong M. Lew, MD, Pam Halthcock, CST, and Barry E. Linden, MD, for their professional contributions. We also thank Ann Morris for editorial assistance.

Presented at the Fifth Annual Meeting of the American Society of Pediatric Otolaryngology, Toronto, Canada, May 16-19, 1990.

Address reprint requests to Dr. Lazar, Otolaryngology Consultants of Memphis, Le Bonheur Children's Medical Center, 848 Adams Avenue, Memphis, TN 38103.

Accepted for publication August 28, 1991.


CCC 0148-6403/92/02092-07 \$04.00  
© 1992 John Wiley & Sons, Inc.

The introduction of fiberoptic technology motivated many otolaryngologists to alter their approach to treating sinus disease and the manner in which they perform surgery. Although endonasal sinus surgery, which uses the fiberoptic telescope, is relatively new in the United States, treatment of chronic or recurrent sinusitis using functional endonasal sinus surgery (FESS) has become popular among otolaryngologists during the last 5 years.

This technique was introduced in Europe in the late 1970s by Messerklinger and Stammberger.<sup>1-3</sup> In the United States, FESS was popularized by Kennedy for the treatment of adult patients.<sup>4</sup> It was not until Gross and his colleagues reported their experience with 57 pediatric patients that FESS became an accepted treatment for children.<sup>5</sup>

FESS is a functional, rather than ablative or exenterative, procedure. Conditions in the frontal and maxillary sinuses depend largely on the physiologic state of the anterior ethmoid sinuses. Therefore, improving drainage in this critical area often restores normal physiologic function to all three sinuses.

The procedure for children is similar to that described for adults, except that surgery for all pediatric patients with chronic or persistent sinusitis is done under general anesthesia and that follow-up endoscopic cleaning in the office is seldom possible for children. This necessitates a second-stage endoscopic cleaning under general anesthesia, which is usually sufficient



to permit proper healing without further endoscopy.

Data for long-term follow-up of the patients undergoing FESS have only recently begun to appear in the literature and are not yet conclusive. Consequently, as experience is gained with FESS, it is important to examine long-term results and late complications. In this communication, we report our technique, results, and complications of pediatric FESS based on a review of our experience with 210 pediatric patients during a 3-year period.

#### **MATERIALS AND METHODS**

**Patients.** From June 1986 through June 1989, 210 pediatric patients (age range, 14 months to 16 years) were evaluated and underwent FESS. The children were treated by members of the Otolaryngology Consultants of Memphis at Le Bonheur Children's Medical Center. A physical examination and history were documented for each patient. Allergy history, past medical history, and family medical history were obtained.

Patients were considered to have chronic sinusitis if their symptoms had persisted for more than 3 months despite maximal medical treatment, which is delineated later in this report. Symptoms of chronic sinusitis include persistent cough, nasal congestion or obstruction, and headache with facial pain or pressure. The signs of chronic sinusitis include persistent or recurrent purulent anterior rhinorrhea or postnasal discharge, recurrent otitis media, erythematous boggy nasal mucosa, nasal polyposis, and facial or periorbital swelling. Chronic or recurrent sinusitis was diagnosed if a patient presented with frequent attacks of acute sinusitis or if a patient with chronic sinusitis developed frequent exacerbations.

All patients received 3 weeks of optimal medical therapy before surgery was considered. Pre-surgical therapy consisted of cefaclor (40 mg/kg/day) or amoxicillin clavulanate potassium (40 mg/kg/day), and beclomethasone nasal spray. At times, a nasal decongestant spray, mucolytic agents, and decongestant were used. Except for the nasal spray (5 days), this regimen was administered for 3 weeks.

Most patients were referred for allergy assessment by a pediatric otolaryngic allergist or a pediatric allergist. Asthmatic patients were assessed by a pediatric pulmonologist, and all had allergy evaluations. Allergy evaluation consisted of prick and intradermal skin testing for inhal-

ant and food allergies. Patients with confirmed allergies were treated by our allergy consultants and followed the same medical protocol as the other patients.

Patients were seen 3 to 4 weeks after initiating medical management. If the symptoms persisted, a coronal computed tomographic (CT) scan of the sinuses persisted, a coronal computed tomographic (CT) scan of the sinuses was obtained. If there was marked improvement, the drug regimen was continued for 3 additional weeks, for a total of 6 weeks of the drug protocol. Patients whose sinusitis persisted despite medical treatment and who had positive CT scans, were scheduled for FESS.

**Techniques.** The technique and principles of FESS are essentially the same for children and adults, but there are a few different steps in the preoperative assessment, type of anesthesia, and postoperative follow-up of pediatric patients.

Because office nasal endoscopy is not well tolerated by children, it was not universally performed. A high-resolution coronal CT scan of the child's sinuses was a valuable aid for therapeutic planning and for ascertaining the extent of sinus development and minor variations from normal that might be surgically significant in the young patient.

General anesthesia was used for all pediatric patients. However, before arrival at the operating suite, topical decongestant spray, either Neo-Synephrine or Afrin was applied. This helped to achieve our initial goal, which was optimal vasoconstriction. After administration of general anesthesia, the surgical site was injected, using a 27-gauge, 3.8-cm needle and a 1.8-mL dental car-pule, with 2% lidocaine and 1:100,000 epinephrine for topical anesthesia and vasoconstriction. Some physicians use 2% lidocaine with 1:50,000 epinephrine. In consultation with the anesthesiologist, the total maximal dose was individualized according to the patient's weight, age, and physiologic status. When injecting epinephrine, the selection of the anesthetic agent is crucial, because major cardiac arrhythmias may occur, and good communication with a pediatric anesthesiologist is essential.

Although Neo-Synephrine or Afrin may be used, in our experience, cocaine provided the best vasoconstrictive effect, in addition to serving as a topical anesthetic agent. In each of our patients, the nose was packed with cottonoid pledgets soaked in a solution of 4% cocaine. Sur-

gery must be delayed at least 10 minutes after injection to allow for the maximal effect of epinephrine and other agents. No arrhythmias occurred in any of the 210 patients during surgery.

Using the modified Messerklinger approach, similar to that used for adults, we performed bilateral FESS for 210 patients (420 procedures). In all procedures, the Storz-Hopkins nasal endoscopes with xenon light sources were used. The 40mm 0° telescope was used for the ethmoid and sphenoid sinuses; the 4-mm 30° telescope was used for the frontal recess and the maxillary sinus. Despite the smaller anatomy of our young patients, the procedures were easily performed with the 4-mm endoscopes. The 2.7-mm telescopes were used only rarely because they did not provide the depth of field nor the degree of visualization or illumination provided by the larger telescopes. We occasionally used the 4-mm 70° telescope to visualize the frontal recess or the maxillary sinus.

Surgery began with nasal endoscopic examination of the septum, the middle turbinate, the posterior nasal airway, and the adenoids. If a deviated septum or a large middle turbinate was discovered, we usually performed a limited septoplasty or a partial middle turbinectomy before starting the FESS procedures. This gave better exposure during the procedure and facilitated aeration and drainage of the sinuses.

An incision was made using a sickle knife along the anterior border of the uncinate process from the superior edge to the posteroinferior edge to create an infundibulotomy. The anterior ethmoid air cells were opened and totally evacuated. The basal lamella was identified and opened. The posterior ethmoids were inspected, and they were exenterated only if there was disease. A common finding was that there was more extensive disease discovered intraoperatively than had been demonstrated by the CT scan. In children, the sphenoids were not opened unless there was evidence of disease on the CT scans.

Using a 30° telescope, we inspected the frontal recess. Polyps and diseased mucosa were removed using upbiting forceps and right-angled suction. The natural ostium of the maxillary sinus was enlarged three to five times using the Gruenwald, upbiting, and sidebiting forceps, taking care not to injure the nasolacrimal duct anteriorly and the sphenopalatine artery posteriorly as the "antrostomy" was created. The maxillary

sinus was then copiously lavaged with normal saline solution.

We emphasized extreme care in handling the forceps, suction, and nasal endoscopes to minimize trauma and reduce postoperative edema and adhesions. The actual operating time was usually 30 to 60 minutes, and blood loss was between 10 mL and 50 mL.

At the end of procedure, 40 mg of methylprednisolone were injected in the surgical site and the anterior surface of the inferior turbinate. Antibiotic steroid ointment was then placed in the ostiomeatal complex. Few patients required postoperative nasal packing with neurosurgical cottonoid pledgets soaked in a 4% cocaine solution. In all instances, this packing was removed in the recovery room before the patient was transferred to the day-care surgery unit. The patient was usually discharged the day of surgery.

Meticulous postoperative follow-up was employed. Every patient was started postoperatively on a steroid nasal spray, a nasal decongestant, saline nasal mist, and a broad-spectrum oral antibiotic. This regimen was employed for 6 weeks. The patients were weaned off the steroid spray and other medications during the last 2 weeks of this therapy.

Patients were seen for their first postoperative visit 10 to 14 days after surgery, and they were scheduled for nasal endoscopy 2 to 3 weeks after surgery. Postoperative nasal endoscopy, performed under general anesthesia, allowed accurate inspection of the surgical site and removal of the instilled ointment, crust, blood clots, granulation tissue, or adhesions. The recently created maxillary sinus ostium was assessed, cleaned, and re-enlarged if necessary. The maxillary sinus was then lavaged with normal saline solution.

The approach and instruments used in this second-look surgery were the same as those for the primary surgery. At the termination of the second procedure, 40 mg of methylprednisolone were injected, and the surgical site was packed with antibiotic steroid ointment.

Each patient returned weekly for 3 weeks and then once every 3 months for 1 year for follow-up examinations. Rarely, a patient required a third procedure.

## RESULTS

The charts of 210 patients who were evaluated and operated on by a member of the Otolaryngology Consultants of Memphis at Le Bonheur Chil-

dren's Medical Center were reviewed. The follow-up period ranged from 3 to 36 months (mean, 18 months).

There were 145 boys and 65 girls, with a male-to-female ratio of 2.2:1. The age range of the patients at the time of surgery was 14 months to 16 years. The age distribution is shown in Figure 1.

There were various presenting symptoms, but nasal drainage and persistent cough were the most common complaints (Table 1). The types of cough and nasal discharge were independent of the diagnosis: the nasal discharge was either thin and milky or thick and purulent; the cough was either dry or associated with sputum production.

All 210 patients had unsuccessful attempts at prior medical management, including broad-spectrum oral antibiotics, decongestants, steroid nasal sprays, and antihistamines. We provided the medical management for all cases. At least one 3-week course of treatment was strictly employed to ensure that all patients had received maximal medical treatment.

Many patients had previous, related surgeries. Tonsillectomies and adenoidectomies had been performed in 54% of the cases, pressure-equalizing tubes in 48%, nasal antral windows in 29%, septoplasties in 10%, inferior partial turbinectomies in 8%, and intranasal ethmoidectomies in 1.4% (Table 2). Many of these procedures were performed elsewhere.

Allergy evaluation was performed for 196 of the 210 patients. Ninety-seven (46%) patients had positive test results, and 99 (47%) patients had negative results. The figures demonstrate that a high percentage of patients with sinusitis may have concomitant allergies. We recommend allergy evaluation for patients presenting with

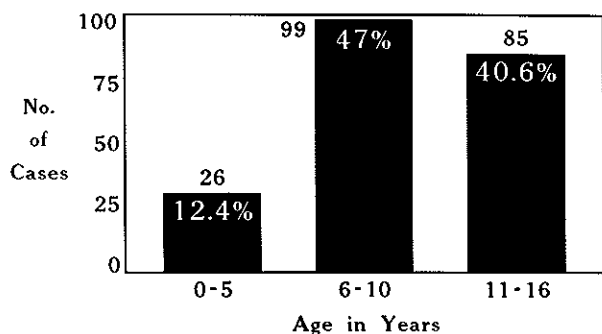


FIGURE 1. Distribution graph of the ages of FESS patients at the time of surgery.

Table 1. Symptoms of chronic sinusitis and age distribution.

Symptoms	14 mo- 3 yr	4- 6 yr	7- 12 yr	13- 16 yr
Chronic cough	++++	++++	+++	++
Anterior rhinorrhea	+++	+++	+++	++
Posterior rhinorrhea	++++	++++	++	++
Nasal congestion	+++	+++	+++	+++
Chronic otitis media and effusion	++++	+++	++	+
Headache	n/a	+++	+++	++++

chronic or recurrent sinusitis. Fourteen (6.7%) patients had no testing done. Additionally, 45 (22%) of the 210 patients were asthmatic. Almost 63% of the patients younger than 8 years had recurrent otitis media. This incidence dropped to 41% in children between 9 and 16 years of age.

For the 210 patients who underwent FESS, all procedures were bilateral (420 procedures). Nine percent had concomitant septoplasty, 7% had partial resection of the middle turbinate, 18% had tonsillectomies and adenoidectomies, and 25% had pressure-equalizing tube insertions at the time of FESS (Table 3). All patients had nasal endoscopy under general anesthesia 2 to 3 weeks after surgery.

Each FESS procedure required 30 to 60 minutes (mean, 45 minutes). The mean blood loss was 20 mL (range, 10 to 50 ml). Eight (3.8%) patients bled after the FESS procedure, but bleeding was controlled by packing the nose for 1 to 2 hours with neurosurgical cottonoid pledgets soaked in a 4% cocaine solution. No packs were kept in place, and no patient had postoperative bleeding that required readmission or transfusion.

Five patients developed orbital ecchymosis, three patients developed dacrocystorhinitis, and three patients complained of severe ear pain. No patient developed blindness, cerebrospinal fluid

Table 2. Previous related surgeries and age distribution.

Previous surgeries	14 mo-6 yr (%)	7-16 yr (%)
Tonsillectomies and adenoidectomies	20	34
Pressure-equalizing tubes	34	14
Nasal-antral windows	12	17
"Limited" septoplasty	0	10
Partial inferior turbinectomy	0	8
Intranasal ethmoidectomy	0	1.4

**Table 3.** Concomitant surgeries and age distribution.

Concomitant surgeries	14 mo-6 yr	7-16 yr
	(%)	(%)
Tonsillectomies and adenoidectomies	6	12
Pressure-equalizing tubes	25	4
"Limited" septoplasty	0	9
Partial middle turbinectomy	10	6

rhinorrhea, extraocular muscle injury, or meningitis.

Sixteen (8%) patients had revision FESS. The revision surgery was done within the first year. It was indicated only if the patient failed to respond to additional optimal medical treatment. Twelve of the 16 revision cases had middle meatal stenosis, two of which were bilateral. In the cases re-operated within 6 months of the initial FESS, persistent frontal recess polyps were found during revision surgery. Most of these cases occurred early in this series, at a time when we were not cognizant of the importance of this area in very young patients.

The postoperative findings during nasal endoscopy varied. Adhesions, found in 20% of the patients, commonly formed between the middle turbinate and the septum. In most cases, these were lysed and required no further surgery. Ten percent of the patients had granulation tissue formation, 7% had persistent polyposis, and 11% had significant crusting (Table 4).

Of the 210 patients who underwent FESS, 165 (79%) patients were considered successfully treated. Of the 45 patients who had persistent symptoms after FESS, 29 improved after additional medical treatment.

To further validate the results of our review, a questionnaire was designed and mailed to the parents or primary caretakers of all 210 patients. For this survey, we inquired about the patient's allergy history, presenting symptoms, and results of surgery. The parents or caretakers were asked to evaluate the results of surgery on

**Table 4.** Postoperative nasal endoscopy results.

Endoscopic findings	Percent of patients
Adhesions	20
Granulation tissue	10
Significant crusting	11
Persistent polyposis	7

a scale of 0 to 10, with 0 representing no change in symptoms and 10 representing cure.

The improvement was further classified as (1) no or poor improvement if the grading was between 0 and 3; (2) moderate improvement if the grading was between 4 and 6; and (3) marked improvement if the grading was between 7 and 10. A patient was considered to have improved if his or her grading was between 4 and 10. The results of improvement grading for each complaint are summarized in Table 5.

Of 210 patients (parents), 103 (49%) responded. Of the responders, 53% were parents of patients 14 months to 6 years old, and 47% were parents of children 7-16 years old at the time of surgery. Eighty-eight percent of those responding stated that they would recommend the surgery. Among the children of the 103 responders, 80% had chronic nasal obstruction, 73% had chronic cough, 63% had chronic nasal discharge, and 61% had chronic headache as their presenting complaints. All responders graded the improvement of these complaints.

Chronic nasal obstruction improved in 84% of the cases, cough in 85%, nasal discharge in 83%, and headaches in 84%. An element of bias should be considered in this survey, because only 49% of the parents responded. Moreover, most of those responding were parents of patients who had significant improvement or were cured after surgery.

#### COMMENT

Sinusitis has become the number one chronic illness for all age groups in the United States according to the National Center for Disease Statistics.<sup>6</sup> Approximately one in eight persons suffers from sinusitis at some time in his or her life. Although the exact incidence of sinusitis in

**Table 5.** Results of patient questionnaire.

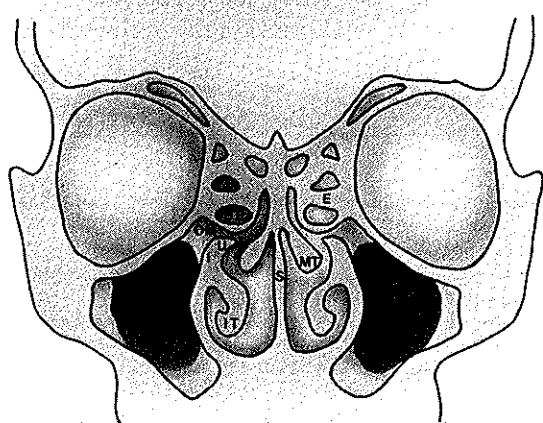
Presenting symptoms (no. of patients)	Improvement (% of patients)			
	No/poor (0-3)	Moderate (4-6)	Marked (7-10)	Total (4-10)
Chronic headache (128)	16	24	60	84
Chronic nasal discharge (132)	17	20	63	83
Chronic nasal obstruction (168)	16	21	63	84
Chronic cough (153)	15	23	62	85

children is unknown, it is a common disease in the pediatric age group.

There are many predisposing factors for sinusitis, but upper respiratory tract infection and allergy are the most common causes.<sup>7</sup> Sinusitis is usually not an isolated process in children. Adenotonsillar hypertrophy or infection, allergy, chronic otitis media, cleft palate, or septal deviation may be associated with the disease, and these should be looked for and treated in every child presenting with sinusitis. Many asthmatic children have their asthma exacerbated by sinusitis.<sup>8</sup> Because of the complex nature of the disease, the management of a child with sinusitis frequently is best done by a team of several physicians.

The most common pathophysiologic process leading to sinusitis is ostiomeatal complex obstruction. The ostiomeatal complex is the region of the middle meatus where the pathway of mucociliary flow converges from the frontal, maxillary, and ethmoid sinuses. It consists of the infundibulum, hiatus semilunaris, frontal recess, uncinate process, anterior ethmoid cells, ethmoid bulla, and the anterior wall of the middle turbinate (Figure 2).

The primary purpose of FESS is the restoration of mucociliary flow in the region of the ostiomeatal complex. It follows that FESS is essentially surgery of the ostiomeatal complex, with or without other added features. The technique frequently includes opening the ostiomeatal complex and removing sinus disease with minimal manipulation of surrounding normal tissue. The



**FIGURE 2.** Anatomy of the ostiomeatal complex. M, maxillary sinus; MT, middle turbinate; E, ethmoid sinus; S, septum; IT, inferior turbinate; U, uncinate process; I, infundibulum; BE, bulla ethmoidalis; OM, ostiomeatal complex; arrow, hiatus semilunaris.

data from this series demonstrate that FESS is an excellent treatment for chronic or recurrent sinusitis in children and that the procedure is indicated whenever a child fails to respond to an optimal medical treatment regimen.

All patients in this series were referred to us by their pediatricians or allergists after failure of maximal medical treatment. We placed all patients on additional optimal medical treatment for 3 to 4 weeks before FESS was considered.

Because the anatomy and extent of sinus development of children is different from adults, variations in technique are frequently required. Specifically, the smaller intranasal anatomy of children makes the surgical site more vulnerable to trauma. It follows that the surgeon performing pediatric FESS should have a thorough knowledge of the sinonasal anatomy and should personally review the patient's CT scan before and during the surgery. A preconceived surgical plan is important in reducing trauma and minimizing postoperative morbidity. Despite careful planning, the surgeon must be flexible because the intraoperative nasal endoscopy may reveal certain abnormalities that are not evident on CT scans.

Postoperative care is also different for children and adults. Because children do not tolerate office endoscopy well, an endoscopy or repeat examination and cleaning must be done under general anesthesia 2 weeks after primary FESS. This waiting period allows sufficient healing of the surgical site but is not long enough for excessive synechia formation.

The success of our surgical procedures was assessed by the physician's and by the patient's or caretaker's evaluations. Based on our own assessment and follow-up, 165 (79%) of the 210 patients who underwent bilateral procedure were relieved of their symptoms by FESS. The evaluation by the patients or parents showed almost the same success rate, although only 49% of those queried responded (Table 5).

Although assessments show that FESS is a successful surgical procedure for the treatment of chronic or recurrent sinusitis in children, the morbidity and complications should also be considered. There were no major complications. Nineteen (9%) of 210 patients did develop minor postoperative complications: eight had immediate postoperative bleeding, five had ecchymosis, three had dacryocystorhinitis, and three had severe ear pain.

Adhesions were the major postoperative find-

ings by endoscopic examination (Table 4). This condition can lead to ostiomeatal and middle meatal stenosis and sinusitis recurrence if it goes unnoticed. To avoid adhesions, we recommend injecting methylprednisolone at the termination of surgery and the use of steroid spray for 6 weeks postoperatively. Reducing trauma during surgery by meticulous handling of tissue and decreased manipulations can further diminish the formation of adhesions. If adhesions do occur, very close follow-up, lysis, and treatment with topical steroids is indicated.

Allergy plays a major role in the occurrence of chronic or recurrent sinusitis in children. Of 210 patients, 97 (46%) had positive results for allergy testing. Because allergy is one of the most common predisposing factors for sinusitis, an evaluation by a pediatric otolaryngic allergist or a pediatric allergist is essential for every child presenting with persistent sinusitis. Almost 80% of asthmatic patients reported that their asthma improved after FESS.

All the patients for whom FESS failed had their disease for a prolonged period. These patients also tested positive for allergies. Of those who failed, four patients had immunodeficiencies, two had cystic fibrosis, and one had immotile cilia syndrome as documented by tissue biopsy results or serology studies, or both. Immunodeficiency should be suspected in children with persistent chronic sinusitis. In our study, almost 6% of patients had test results consistent with immunodeficiency, and most of these children improved with surgery in conjunction with medical therapy. Immunodeficiency testing consisted of obtaining immunoglobulin quantitative analysis and evaluation of IgG subclasses. Patients with proven deficiencies were treated

appropriately by their pediatric immunologists. IgA deficiency was the most common finding in patients with immunodeficiencies.

The results of our review suggest that FESS is a successful surgical procedure with minimal morbidity for several reasons. It is performed under direct visualization with clear illumination of the sinonasal cavity. It corrects the physiologic problems of the ostiomeatal complex. Moreover, diseased tissues are removed, but normal tissues are left untouched, and the surgery is performed in a meticulous fashion with minimal manipulation. All of these factors contribute to the favorable outcome of FESS in the treatment of chronic or recurrent sinusitis. The procedure has a high success rate with low morbidity, but we stress that these encouraging results are obtained only if FESS is performed by an experienced, well-trained surgeon with a proven preoperative, intraoperative, and postoperative regimen.

FESS is a cost-effective treatment for chronic or recurrent sinusitis in children who have failed to respond to optimal medical therapy. Failure is more likely to occur in patients with long-standing refractory sinusitis, which appears to increase in frequency among patients with systemic abnormalities (e.g., cystic fibrosis or immotile cilia syndrome).

Based on our results from operating on 210 patients, FESS is currently recommended as the surgical procedure of choice for chronic or recurrent sinusitis in children after medical treatment has proven ineffective. A final assessment of this surgical approach can only be obtained from studying a larger series of patients, who are more carefully evaluated and followed for a longer period.

## REFERENCES

1. Messerklinger W. Endoscopy of the nose. Baltimore, MD: Urban Schwarzenberg, 1978.
2. Stammberger H. Endoscopic endonasal surgery—concepts in treatment of recurring rhinosinusitis. I. Anatomic and pathophysiologic considerations. *Arch Otolaryngol Head Neck Surg* 1986;94:143–146.
3. Stammberger H. Endoscopic endonasal surgery—concepts in treatment of recurring rhinosinusitis. II. Anatomic and pathophysiologic considerations. *Arch Otolaryngol Head Neck Surg* 1986;94:147–156.
4. Kennedy DW, Zinreich SJ, Rosenbaum AE, et al. Functional endoscopic sinus surgery: theory and diagnostic evaluation. *Arch Otolaryngol* 1985;111A:576–582.
5. Gross CW, Guruchiari MJ, Lazar RH, Long TE. Functional endonasal sinus surgery (FESS) in the pediatric age group. *Laryngoscope* 1989;99:272–275.
6. Levine HL. Functional endoscopic sinus surgery: evaluation, surgery, and follow-up of 250 patients. *Laryngoscope* 1990;100:79–83.
7. Wald ER. Diagnosis and management of acute sinusitis. *Pediatr Ann* 1988;17:629–638.
8. Slavin RG. Sinus disease and asthma. *Ear Nose Throat J* 1984;63:48–56.